

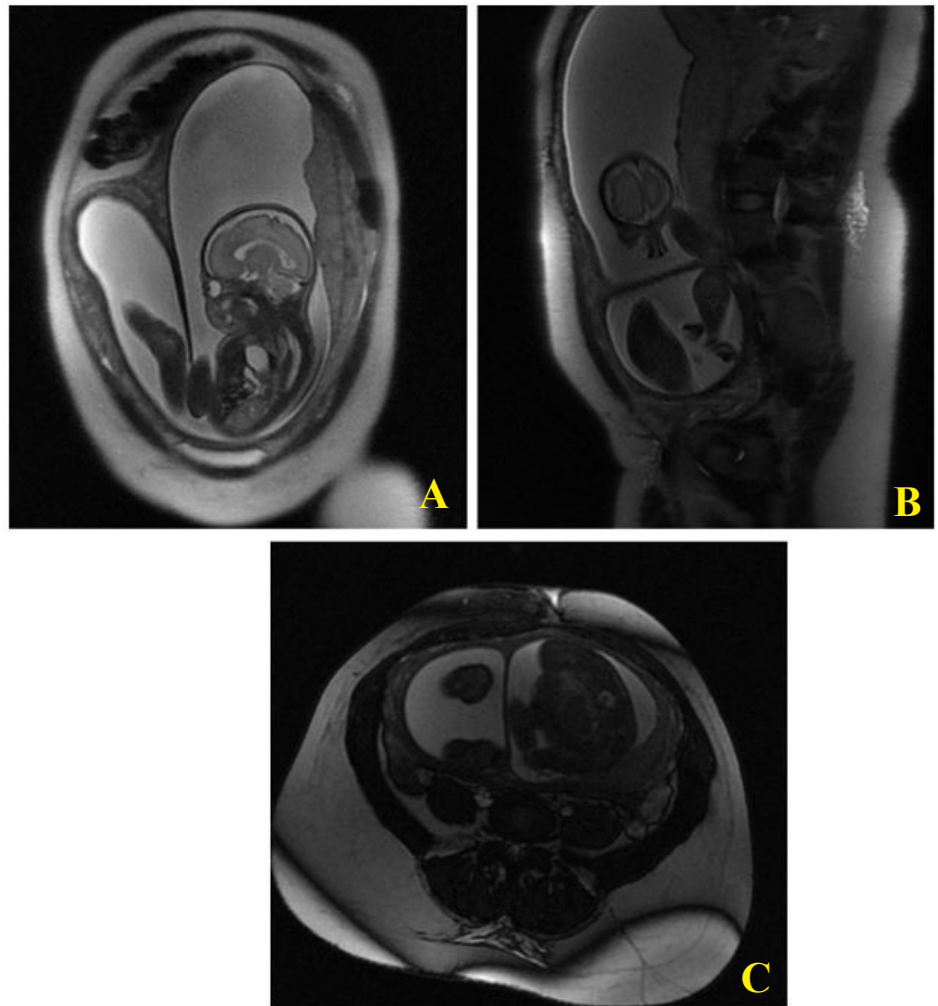
***Corresponding author**

*Benchaaboune kenza, Department of Industrial Engineering, National School of Applied Sciences, Sidi Mohamed Ben Abdellah Fès University (USMBA), Fez 30003, Morocco.

A case of successful pregnancy in a partial septate uterus

Benchaaboune kenza

Department of Industrial Engineering, National School of Applied Sciences, Sidi Mohamed Ben Abdellah Fès University (USMBA), Fez 30003, Morocco



The magnetic resonance images show in a) coronal section, b) sagittal section, c) transverse section:

A partial uterine fundal septum, class U2a according to the ESHRE/ESGE classification, in a 35 year old patient with a history of miscarriage, who presented with a threat of premature delivery, associating uterine contractions with a cervix at 22 mm on endovaginal ultrasound, at the age of 28 SA. It should also be noted that the fetal MRI showed a diaphragmatic hernia.