

***Corresponding author**

*Arifa Aziz, Staff Medical Officer,
Department of Oncology, The Aga
Khan University Hospital, Karachi,
Pakistan.

Audit on incidence of Trastuzumab induced Cardiac toxicity in day care Oncology at a tertiary care hospital, Karachi, Pakistan.

Arifa Aziz^{1*}, Adeeba Zaki², Iffat Shehzad³

¹Staff Medical Officer, Department of Oncology, The Aga Khan University Hospital, Karachi, Pakistan

²Senior Instructor, Department of Oncology, The Aga Khan University Hospital, Karachi, Pakistan

³Medical Officer, Department of Oncology, The Aga Khan University Hospital, Karachi, Pakistan

Abstract

Background: Trastuzumab is a monoclonal antibody that inhibits tumor cell growth by binding to the extracellular region of the HER 2 protein and blocking the signalling pathway with overexpressed HER 2 positive breast cancer patients. Mostly presented at an advanced stage and have a significantly shortened disease-free and overall survival. Our objective is to find out the frequency of cardiac toxicity with trastuzumab given subcutaneous,

Method: Questionnaire form for audit was developed which included questions on shortness of breath, palpitation, edema feet, chest pain and echocardiogram report. Trastuzumab is given through subcutaneous route at dose of 600 mg and echocardiogram monitored at every 3 months. Data collected from April 2022 till August 2022.

Result: Fifty patients' data was collected, out of these only one patient developed shortness of breath. and chest pain. Two echocardiograms' reports were checked at an interval of three months, both showing normal ejection fraction (55% to 60%).

Conclusion: Cardiac toxicity is minimal with trastuzumab given subcutaneously.

Introduction

Trastuzumab induced cardiotoxicity is generally reversible and can usually be managed with medical treatment. Cardiac function is improved both in patients who continue trastuzumab and in those in whom further therapy is withdrawn, indicating that with careful cardiac management by cardiologist, anticancer therapy can be continued. It is generally accepted that, unlike anthracyclines, the cardiotoxicity caused by trastuzumab is not dose-dependent, does not occur in all patients, and is reversible. (1)

It is important in the management of both early and advanced disease. It improves survival in advanced breast cancer patients. Symptomatic heart failure is the adverse effect caused by this antibody seen in intravenous trastuzumab infusion (2). The most common immediate side effects seen in treatment of metastatic breast cancer with intravenous trastuzumab are fever, chills, headache, infection, congestive heart failure, insomnia, cough, and rash. women who are pregnant or planning to get pregnant should not take trastuzumab because it can harm the developing foetus (3)

It usually manifests in the form of asymptomatic decrease in left ventricular ejection fraction. Echocardiogram is the tool to monitor ejection fraction in patients receiving this antibody at every three months. Serious and fatal drug

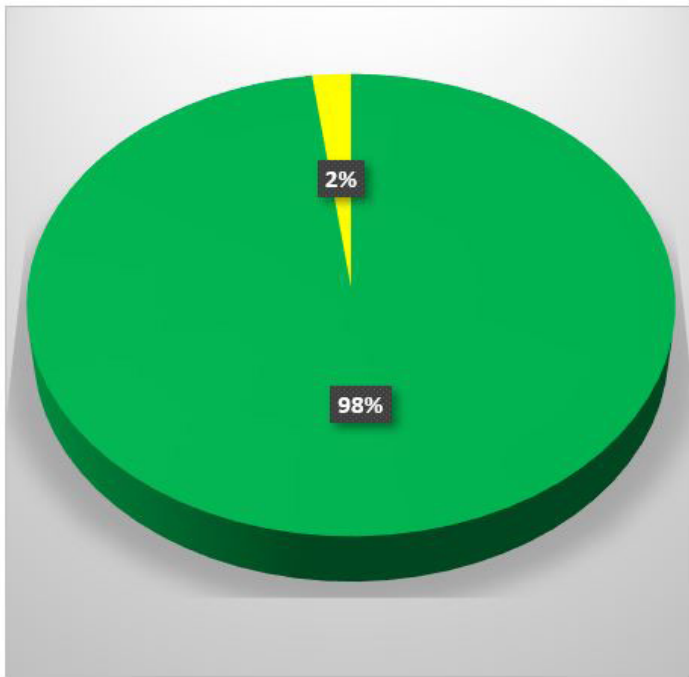


Figure 1: Yellow=developed symptoms
Green=Normal

reactions have been reported with intravenous trastuzumab therapy (4).

Trastuzumab is a subcutaneous formulation that contains hyaluronidase, which temporarily and reversibly degrades hyaluronan, a gel-like substance that forms a barrier between cells under the skin. This enables the subcutaneous formulation of trastuzumab to be rapidly dispersed and absorbed over a greater area (5).

Trastuzumab subcutaneous is approved in combination with chemotherapy for the adjuvant (post-surgery) treatment of HER2-positive early breast cancer and first-line treatment of advanced HER2-positive breast cancer.

In addition to left ventricular dysfunction and heart failure, studies also reported the development of arrhythmias, sick sinus node syndrome, and atrial flutter in patients undergoing treatment with trastuzumab. (6) Recently, through a secondary analysis of a clinical trial, investigators found that trastuzumab induced hypertension

Table 1:

Audit: Incidence of Trastuzumab induced cardiac toxicity.

Case #: MR#: Age (years): Sex: M F

CV risk factors: Smoking Diabetes Dyslipidaemia History of cardiopathy or stroke

Primary Malignancy: Breast

Chemotherapy regimen: A/C followed by Trastuzumab in adjuvant and neo adjuvant setting.

Trastuzumab dose; 600 mg subcutaneous

Duration; every 3 weeklies

Symptoms; SOB Palpitation edama chest pain

Cycles; one two Three Four Five Six Seven Eight Nine

Echocardiogram; 3 monthly

Report Date.

Report Result.

Excluding Criteria

1-H/O Cardiac Disease

2-Metastatic Disease

is characterized by the presence of both left ventricular dysfunction and reversible myocardial inflammation and edema, and that trastuzumab may be associated with harmful changes in cardiac metabolic phenotype (6) .

Improvement in cardiac function is seen both in patients who continue trastuzumab and in those in whom further therapy is withdrawn, indicating that with careful management trastuzumab therapy can be continued, it is generally accepted that, unlike anthracyclines, the cardiotoxicity caused by trastuzumab is not dose-dependent, does not occur in all patients, and is reversible (7).

A frequently used definition of treatment-related cardiotoxicity in clinical trials is an absolute decrease in left ventricular ejection fraction (LVEF) of 10% to a value of <55%

Researchers analysed 1,437 echocardiograms from 324 patients over a follow-up period of up to 3.5 years and revealed three main patterns of Left ventricular ejection fraction (LVEF) slow decline with time mild early and late sustained decline, early significant decline with late partial recovery (8-9).

Method

Questionnaire form for audit was developed which included questions on shortness of breath, palpitation, edema feet, chest pain and echocardiogram report. Trastuzumab is given through subcutaneous route at dose of 600 mg and echocardiogram monitored at every 3 months. Data collected from April 2022 till August 2022.

Inclusion Criteria:

1. All age group patients with primary diagnosis of Breast cancer.
2. Adriamycin and cyclophosphamide followed by Trastuzumab in adjuvant and neo adjuvant setting. Trastuzumab dose 600 mg subcutaneous.

Exclusion Criteria:

1. Known case of cardiac disease.

Result

Fifty patients' data was collected, out of these only one patient developed shortness of breath. and chest pain. Two echocardiograms' reports were checked at an interval of three months, both showing normal ejection fraction (55% to 60%).

Discussion

Trastuzumab is a monoclonal antibody that targets epidermal growth factor receptor (HER2). HER2 is found in all human cells. It controls cell growth and repair. High levels of HER2 are found in some types of breasts, oesophageal and stomach cancer, which helps the cancer cells grow and survive.

Trastuzumab works against HER2-positive breast cancers by blocking the ability of the cancer cells to receive chemical signals that tell the cells to grow. It can be given in 2 ways:

By intravenous infusion, where the medicine slowly enters blood stream through a drip. The first intravenous treatment usually takes about 90 minutes and further treatments take about 30 minutes to 60 minutes.

By subcutaneous injection, which is given into thigh over 5 minutes, this route of administration can only be used for breast cancer and therefore only subcutaneous route is included in our study for administration of trastuzumab and intravenous route of trastuzumab is not included (10-12)

The cardiotoxicity is generally reversible and can usually be managed with standard medical treatment. Improvement in cardiac function is seen both in patients who continue trastuzumab and in those in whom further therapy is withdrawn, indicating that with careful management anticancer therapy can be continued, it is generally accepted that, unlike anthracyclines, the cardiotoxicity caused by trastuzumab is not dose-dependent, does not occur in all patients, and is reversible (13-15).

Trastuzumab is important in the management of both early and advanced disease. It improves survival in advanced breast cancer patients. Symptomatic heart failure is the adverse effect caused by this antibody.

It usually presents in the form of asymptomatic decrease in left ventricular ejection fraction. Echocardiogram is the tool to monitor ejection fraction in patients receiving this antibody at every three months. Serious and fatal drug reactions have been reported with intravenous trastuzumab therapy. (16-17)

Conclusion

Cardiac toxicity is minimal with trastuzumab when given subcutaneously.

References

1. Chen J, Long JB, Hurria A, Owusu C, Steingart RM, Gross CP. Incidence of heart failure or cardiomyopathy after adjuvant trastuzumab therapy for breast cancer. *J Am Coll Cardiol.* (2012) 60:2504-12. doi: 10.1016/j.jacc.2012.07.068
2. Sandor A, Kitas GD, Carmichael AR. Endothelial dysfunction as a determinant of trastuzumab-mediated cardiotoxicity in patients with breast cancer. *Anticancer Res.* 2014; 34:1147–51.
3. Sendur MAN, Aksoy S, Altundag K. Cardiotoxicity of novel HER2-targeted therapies. *Curr Med Res Opin.* 2013; 29:1015–24. doi:10.1185/03007995.2013.807232.
4. Albanell J, Ciruelos EM, Lluch A, Muñoz M, Rodríguez CA. Trastuzumab in small tumours and in elderly women. *Cancer Treat Rev.* 2014; 40:41–7. doi:10.1016/j.ctrv.2013.04.002.
5. Gonzalez-Angulo AM, Litton JK, Broglio KR, Meric-Bernstam F, Rakkhit R, Cardoso F, et al. High risk of recurrence for patients with breast cancer who have human epidermal growth factor receptor 2-positive, node-negative tumors 1 cm or smaller. *J Clin Oncol.* (2009) 27:5700-6. doi: 10.1200/JCO.2009.23.2025
6. Beser AR, Tuzlali S, Guzey D, Dolek Guler S, Hacihanefioglu S, Dalay N. HER-2, TOP2A and chromosome 17 alterations in breast cancer. *Pathol Oncol Res.* (2007) 13:180-5. doi: 10.1007/BF02893497
7. Witton CJ, Reeves JR, Going JJ, Cooke TG, Bartlett JM. Expression of the HER1-4 family of receptor tyrosine kinases in breast cancer. *J Pathol.* (2003) 200:290-7. doi: 10.1002/path.1370
8. 7-PubMed Abstract | CrossRef Full Text | Google Scholar9- Morrison G, Fu X, Shea M, Nanda S, Giuliano M, Wang T, et al. Therapeutic potential of the dual EGFR/HER2 inhibitor AZD8931 in circumventing endocrine resistance. *Breast Cancer Res Treat.* (2014) 144:263-72. doi: 10.1007/s10549-014-2878-x
9. Jiang Z, Zhou M. Neuregulin signalling and heart failure. *Curr Heart Fail Rep.* (2010) 7:427. doi: 10.1007/s11897-010-0003-y
10. Demissei BG, Finkelman BS, Hubbard RA, Smith AM, Narayan HK, Narayan V, et al. Cardiovascular function phenotypes in response to cardiotoxic breast cancer therapy. *J Am Coll Cardiol.* (2019) 73:248-9. doi: 10.1016/j.jacc.2018.10.057
11. Spector NL, Blackwell KL. Understanding the mechanisms behind trastuzumab therapy for human epidermal growth factor receptor 2-positive breast cancer. *J Clin Oncol.* (2009) 27:5838-47. doi: 10.1200/JCO.2009.22.1507
12. Kirkham AA, Pituskin E, Thompson RB, Mackey JR, Koshman SL, Jassal D, et al. Cardiac and cardiometabolic phenotyping of trastuzumab-mediated cardiotoxicity: a secondary analysis of the MANTICORE trial. *Eur Heart J Cardiovasc Pharmacother.* (2021). doi: 10.1093/ehjcvp/pvab016 [Epub ahead of print].
13. Zamorano JL, Lancellotti P, Munoz DR, Aboyans V, Asteggiano R, Galderisi M, et al. [2016 ESC position paper on cancer treatments and cardiovascular toxicity developed under the auspices of the ESC Committee for Practice Guidelines]. *Kardiol Pol.* (2016) 74:1193-233. doi: 10.5603/KP.2016.0156
14. Seidman A, Hudis C, Pierri MK, Shak S, Paton V, Ashby M, et al. Cardiac dysfunction in the trastuzumab clinical trials experience. *J Clin Oncol.* (2002) 20:1215-21. doi: 10.1200/JCO.2002.20.5.1215
15. Demissei BG, Finkelman BS, Hubbard RA, Smith AM, Narayan HK, Narayan V, et al. Cardiovascular function phenotypes in response to cardiotoxic breast cancer therapy. *J Am Coll Cardiol.* (2019) 73:248-9. doi: 10.1016/j.jacc.2018.10.057
16. Kirkham AA, Pituskin E, Thompson RB, Mackey JR, Koshman SL, Jassal D, et al. Cardiac and cardiometabolic phenotyping of trastuzumab-mediated cardiotoxicity: a secondary analysis of the MANTICORE trial. *Eur Heart J Cardiovasc Pharmacother.* (2021). doi: 10.1093/ehjcvp/pvab016 [Epub ahead of print].
17. Karaca M, Kocoglu H, Bilgetekin I, Ozet A, Sahinli H, Demir H, et al. Ventricular bigeminal rhythm associated with trastuzumab: a potential cardiac side effect. *J Cancer Res Ther.* (2018) 14:S536-7. doi: 10.4103/0973-1482.183557
18. Advani PP, Ballman KV, Dockter TJ, Colon-Otero G, Perez EA. Long-term cardiac safety analysis of NCCTG N9831 (Alliance) Adjuvant Trastuzumab Trial. *J Clin Oncol.* (2016) 34:581-7. doi: 10.1200/JCO.2015.61.8413